

# Analysis of Segmentation Methods for Locating Microcalcification in Mammogram Image

J. Jebathangam

Research Scholar, Mother Teresa Women's University, Kodaikanal, Tamilnadu, India.

S. Purushothaman

Associate Professor, Institute of Technology, Haramaya University, Ethiopia.

**Abstract – Image segmentation is the process of partitioning the digital image into sets of pixels. Image segmentation changes the image more meaningful and easier to analyze. The medical images processed by Computer Aided Diagnosis tool (CAD) to detect the abnormalities will be highly successful in identifying the microcalcification. Segmentation is one of the techniques in CAD to process the image. Each segmented image gives some information to the user. Segmentation technique varies for different images depending upon the problem. This paper analyses about the segmentation technique in mammogram images using CAD tool which helps the radiologist to identify the microcalcification and to know the impact of the disease in patients.**

**Index Terms – Image segmentation, microcalcification, mammogram, Computer Aided Diagnosis tool.**

## 1. INTRODUCTION

Image processing is a method to convert images into digital form and perform some operations on it in order to extract some features from it. The purpose of image processing is divided into five groups, they are visualization, Image sharpening, Image retrieval, Measurement of pattern, Image recognition. Some of the applications of image processing are medical field, remote sensing, pattern recognition, video processing and microscopic image. Image processing includes basically these three steps, importing the image through image acquisition tools, analyzing and manipulating the image, output in which result can be altered based on image analysis. A mammogram is an x-ray examination of the breasts, used to detect and diagnose breast diseases. Mammography is the most effective method of detecting cancer at an early stage, before the woman or a physician can feel it. In mammography, the objective is to produce images that provide maximum visualization of breast anatomy and the signs of disease without subjecting the patient to unnecessary radiation. Digital mammography is currently considered as standard procedure for breast cancer diagnosis. COMPUTER-AIDED DETECTION (CADE)-computer based set of algorithms that incorporates pattern recognition and uses sophisticated matching and similarity rules to flag possible finding on digital mammogram images. COMPUTER-ASSISTED DIAGNOSIS (CADx) devices that include software that provides information beyond identifying

suspicious findings, assesses likelihood or absence of disease or disease type. The aim of segmentation is to extract ROIs containing calcification and to correctly identify the suspicious mass candidates from the ROI extracted. Calcification is small calcium deposit in breast which is seen as bright white spots. There are two types of clusters, benign which is noncancerous and malignant which is cancerous. Recently the occurrence of breast cancer has increased but there is a decrease in death rate. Death rate has decreased for women who had periodic screening mammograms.

## 2. CLASSIFICATION OF SEGMENTATION

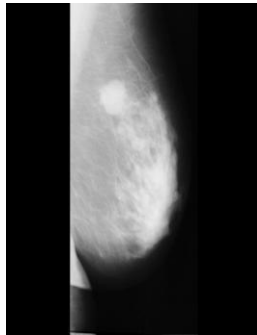
Segmentation can be broadly classified into Region based, Edge based, Threshold, Feature based clustering, Model based. In Region based pixels are grouped, and there is no gap due to missing edge pixels. In each step at least one pixel is related to the region. From this the edges are detected for further segmentation. In Edge based segmentation the boundary is identified to segment. Edges are detected to find out the discontinuities in the image. Both fixed and adaptive feature of support vector machine is used in their classification. Different Edge detection methods are Gradient edge detection, Log edge detection, Canny edge detection, Sobel edge detection, Laplacian edge detection, Robert edge detection. Segmentation in thresholding is done through the threshold values derived from the histogram of the original image. This segmentation technique is not suitable for complex images. In feature based clustering segmentation is done through clustering. K-means is a basic clustering algorithm for segmentation in textured images. Fuzzy clustering technique is used for color images. Model based segmentation is also known as Markov Random Field (MRF). This method is combined with edge detection for identifying the edges accurately. Gaussian Markov Random Field (GMRF), Gaussian Markov Model (GMM) also detects the feature space. These techniques are applicable in different fields like medical imaging, object recognition, pattern recognition etc. In future these techniques have a vital role in Image processing.

## 3. MAMMOGRAPHY PROCESS

Mammography is an X-ray technique for identifying masses in

the breast. In mammography X-ray beam is passed through the tissue to find the variations in amount of radiation absorbed by the tissue. Mammography has been used for about 30 years and in the past 15 years technical advancements have been greatly improved in both results and techniques.

MIAS IMAGE



Digital mammogram transforms the X-ray into an electronic picture of the breast. Female breast contains mostly fibrous and fatty connective tissues. It is divided into lobes which are further divided into lobules. Denser tissues in the breast display brighter intensity. Muscular, masses of both malignant and benign, vascular tissue appear brighter. Intensity is darker in the areas where fat or skin appears. Microcalcification observed in mammograms are calcium deposits located in the breast tissue which highly indicates the presence of cancer in breast.

Mammography is at present the best available technique for early detection of breast cancer. The most common breast abnormalities that may indicate breast cancer are masses and calcifications. Breast cancer is the most common disease in women in many countries. Breast image analysis can be performed using mammography, magnetic resonance, thermography and ultrasound images. Digital mammography is proven as efficient tool to detect breast cancer before clinical symptoms appear. Detection and diagnosis of breast cancer in its early stage increases the chances for successful treatment and complete recovery of the patient. Screening mammography is currently the best available radiological technique for early detection of breast cancer. Using Computer-Aided Detection (CAD<sub>e</sub>) and Computer-Aided Diagnosis (CAD<sub>x</sub>) systems by radiologists can have a significant role in early detection of breast cancer and leads to reduction in mortality rate. Digital mammography is currently considered as standard procedure for breast cancer diagnosis. Mammography imaging is the most commonly used technique to detect breast cancer before appearing the clinical symptoms. Breast cancer in India is in rise and rapidly becoming the leading cancer in females and death toll is increasing at fast rate and no effective way to treat this disease yet. So early detection becomes a critical factor to cure the disease and improve the surviving rate. Generally the

X-ray mammography is a valuable and most reliable method in early detection.

#### 4. SEGMENTATION IN MAMMOGRAM

Extracting the features from the image is a tough task in all the fields. Recently segmentation is implemented by three ways by using, soft computing, Hybrid and partial differential equation (PDE). The principle constituents of soft computing segmentation techniques are fuzzy logic, neural computing and evolutionary computation. Hybrid segmentation is a mix of two techniques like merging of wavelet and neural network, merging of optimization technique and neural network. In partial differential equation lot of physical phenomenon can be described and easily displays related procedure. Various techniques have been used to process the mammogram to reveal the data. The goal of segmentation is to extract ROIs containing masses and identify the patients having masses. Researchers have used several segmentation techniques and their combination.

Petrick [3] used Laplacian of Gaussian filter in conjunction with density weighted contrast enhancement (DWCE). DWCE method enhances the structures within the mammographic image to make the edge detection algorithm able to detect the boundaries of the objects. Zou et al. [4] proposed a method that uses gradient vector flow field (GVF) which is a parametric deformable contour model. After the enhancement of mammographic images with adaptive histogram equalization, the GVF field component with the larger entropy is used to generate the ROI. Ferreira et al. [5] used active contour model (ACM) based on self-organizing network (SON) to segment the ROI. This model explores the principle of isomorphism and self-organization to create flexible contours that characterizes the shapes in the image. Yuan et al. [6] employed a dual-stage method to extract masses from the surrounding tissues. Radial gradient index (RGI) based segmentation is used to yield an initial contour close to the lesion boundary location and a region-based active contour model is utilized to evolve the contour further to the lesion boundary.

Danilo Cesar Pereira et al. developed a computational method to segment breast cancer in mammogram- age taken in Cranio Caudal (CC) and Medio Lateral Oblique (MLO) view [7]. They applied multiple threshold, wavelet transform and genetic algorithm to implement segmentation. The result produced 95% of sensitivity. Shanmugavadivu P and Sivakumar V discussed about the detection of Micro Calcification (MC) cluster based on sobel edge detection method in which fudge factor is replaced with Hurst Co-efficient [8]. Hurst Co-efficient is computed as the difference of fractal dimension and the topological dimension of input image. The proposed method produced better result. Aioub Zeinvand Lorestani et al. applied adaptive neuro-fuzzy system to segment the mammogram image [9]. Threshold limit is considered as 190. Pixels having more than 190 are considered as candidate pixel.

The proposed method produced 95% of sensitivity and 98% of specificity. Sivakumar R et al. applied Fuzzy C-Means to segment the image [10]. Thresholding method is used to identify boundary of the breast. Pectoral muscle is determined and removed using modified tracking algorithm. Mentioned Selection of centre points randomly leads to optimal solution in FCM and suggested it can be solved by using Evolutionary algorithm. Sheng zhou Xu et al. used watershed transformation to obtain the lesion boundary of smoothed morphological gradient image [11]. The proposed method is compared with dynamic programming boundary tracing method and the plane fitting and dynamic programming which produced better performance. Dheeba J and Tamil Selvi discussed about the detection of microcalcification using hybrid of Particle Swarm Optimization (PSO) and FCM[12]. The result produced 88.5% of detection rate. Ying-Che Kuo et al. discussed about the application of PSO to identify the masses [13]. Wavelet transformation is applied to enhance-ment the input image at the initial stage. 94.99% of detection rate is produced by the method. Mini MG, ET al.applied multiplexed wavelet transform i.e. zero-crossings (M-Hdetector) and local extreme (Canny detector) of the wavelet coefficients at different decomposition levels [14]. 95% of sensitivity is produced by both the detectors. Alain Tiedeu et al. developed a method to detect micro- calcification based on texture [15]. Input image is smoothed and subtracted from the contrast enhanced image of the input image. The detection method showed 85.65% of success rate with 2.50 FP image. The classifier showed better classification under ROC with 96.8%. Ted C. Wang and Nicolaos B. Karayiannis implemented wavelet based decomposition as a tool for segmentation. Mammogram is decomposed into different frequency subband [16]. The low frequency subband is suppressed. Mammogram with high frequency is reconstructed which showed the presence of MC. The conclusion is to show the ability of the wavelet in mammogram image to detect MC. Dheeba J et al. proposed Particle Swarm Optimized Wavelet Neural Network (PSOWNN) method to classify normal and abnormal breast tissues [17]. PSOWNN classifier showed 94.167% of sensitivity, 92.105% specificity and 93.671% of accuracy than SONN and DEOWNN. Chun-Chu Jen and Shyr-Shen Yu developed automatic detection classifier which used to classify the abnormal tissues in mammogram [18]. Global equalization transformation, image demonizing, binarization, breast object extraction, breast orientation determination and pectoral muscle suppression were carried out in pre-processing. The proposed method showed 86% of sensitivity with the textural features intensity and gradient. The ADC classifier also showed better performance. Xiaoyong Zhang et al. combined morphological operation and wavelet transform to detect MC [19]. The proposed method detected 92.9% of true MC cluster per image and 0.08% false MC cluster per image. Peyman Rahmati et al. presented a novel Maximum Likelihood Active

Contour Model using Level Sets (MLACMLS) [20]. Segmentation contour is estimated using gamma distribution. Proposed algorithm is compared with Adaptive Level Set-Based Segmentation Method (ALSSM) and Speculation Segmentation using Level Sets (SSLS). The accuracy of MLACMLS is 86.85% whereas ALSSM is 74.32% and SSLS is 57.11%. The results are qualitatively compared with active contour and showed better performance. Rahimeh Rouhi et al. developed two methods to segment the masses from the input image. In the first method automated region growing is used to segment in which threshold is obtained by Artificial Neural Network [21]. In the second method, the Cellular Neural Network (CNN) is used to segmentation in which parameters are obtained by a Genetic Algorithm (GA). The proposed method is compared with random forest, naïve Bayes, SVM, and KNN classifiers. The developed method obtained sensitivity 96.87%, specificity 95.94%, and accuracy 96.47%. Shradhananda Beura et al. implemented a method to classify breast tissues as normal, benign or malignant using wavelet and Grey-Level-Co-Occurrence Matrix (GLCM) [22]. The performance was compared with respect to accuracy and AUC of ROC. For normal and abnormal 98.0% of accuracy and for benign and malignant 94.2% of accuracy has been obtained in Mammographic Image Analysis Society (MIAS) database. In Digital Database for Screening Mammography (DDSM) database for the same parameters 98.8% and 97.4% were obtained.

Subodh Srivastava et al. implemented a combined approach for enhancement and segmentation using modified FCM in wavelet [23]. Proposed unsharp masking and sharpening method based on nonlinear complex diffusion. Proposed enhancement method is evaluated using Signal-To-Noise Ratio (SNR). Proposed segmentation is evaluated in terms of Random Index (RI), Variation of Information (VOI) and Global Consistency Error (GCE). The evaluated result shows that execution time of segmentation method is less than the other method used for comparison. Monica Jenefer and Cyrilraj proposed iterative modified watershed algorithm to segment the input image [24]. Speckle Noise Removal and EM algorithm is used for enhancing the image. GLCM is used for feature extraction. Classification is done using SVM. Performance metrics showed Sensitivity is 97.5%, Specificity is 100% and accuracy is 98%.

Arnau Oliver et al. analyzed the mammogram image taken in different views [25]. The images of two different databases are taken and seven mass detection methods are compared. The review is performed on detection of mass in single view-region based, contour based, clustering based and model based. They determined that Integrating Ipsilateral, bilateral and temporal mammogram detection results showed better improvement. Ramani R et al. reviewed various recent enhancement and segmentation techniques applied in mammogram image for the segmentation of the MC [26]. Shanmugavadivu P et al.

proposed a novel segmentation method based on wavelet. Median filter is used for denoising the input image [27]. The result showed the abnormal region exactly. Saleem Durai et al. proposed intensity based method to identify the mammogram is normal or abnormal [28]. The suspicious area is determined by threshold value greater than 140 and area has more than 100 pixels. The proposed method produced accuracy 91.66%, sensitivity 95% and specificity 85%. Dubey RB, et al. proposed segmentation of masses using level set a method [29]. They use Gaussian filter for smoothing and noise reduction. The results are analyzed visually by expert radiologist. Venkat Narayana Rao T and A. Govardhan proposed Fuzzy Enhanced Mammogram Segmentation (FEMS) in which two sub methods FEM1 and FEM2 are developed [30]. The performances of the two methods are evaluated using Similarity Index, Correct Detection Ratio and Under Segmentation Error. FEM1 performs well than FEM2. CDR for FEM1 is 87% while FEM2 gives 77% and consumes 6.25 times lesser processing time.

## 5. CONCLUSION

Digital mammography screening program can enable early Detection and diagnose the breast cancer which increases the chance of complete recovery and decrease mortality.

Various methods have been developed to segment the mammogram image and to assist the radiologists to make the decision. Methods that are commonly used are commonly used are discussed in this paper. This paper analyses the different methods used by other researchers in segmenting the mammogram images. From this survey it is identified that any hybrid technique yields good result, accuracy in classifying the mammogram images.

## REFERENCES

- [1] Gonzalez RC. Digital Image Processing. 3rd ed. India: Pearson Education India; 2009.
- [2] Banerjee S, Ray R, Shome SN, Sanyal G. Noise induced feature enhancement and object segmentation of forward looking SONAR image. *Procedia Technology*. 2014; 14:125–32.
- [3] Petrick, N., Chan, H.P., Sahiner, B., Wei, D.: An Adaptive Density Weighted Contrast Enhancement Filter for Mammographic Breast Mass Detection. *IEEE Transactions on Medical Imaging* 15(1), 59–67 (1996)
- [4] Zou, F., Zheng, Y., Zhou, Z., Agyepong, K.: Gradient Vector Flow Field and Mass Region Extraction in Digital Mammograms. In: 21st IEEE International Symposium on Computer-Based Medical Systems, CMBS 2008, Jyväskylä, June 17–19, pp. 41–43 (2008)
- [5] Ferreira, A.A., Nascimento Jr., F., Tsang, I.R., Cavalcanti, G.D.C., Luderemir, T.B., de Aquino, R.R.B.: Analysis of Mammogram Using Self-Organizing Neural Networks Based on Spatial Isomorphism. In: Proceedings of International Joint Conference on Neural Networks, IJCNN 2007, Orlando, Florida, USA, August 12–17, pp. 1796–1801 (2007)
- [6] Yuan, Y., Giger, M.L., Li, H., Sennett, C.: Correlative Feature Analysis of FFD Images. In: Giger, M.L., Karssemeijer, N. (eds.) *Proc. of SPIE Medical Imaging 2008: Computer-Aided Diagnosis*, vol. 6915 (2008)
- [7] Pereira DC, Ramos RP, Zanchetta do Nascimento M. Segmentation and detection of breast cancer in mammograms combining wavelet analysis and genetic algorithm. *Computer Methods and Programs in Biomedicine*. 2014; 114(1):88–101.
- [8] Shanmugavadivu P, Sivakumar V. Fractal-based detection of microcalcification clusters in digital mammograms. *Proceedings of ICECIT; 2012 Dec 21–23; Anantapur, Andhra Pradesh, India; Elsevier*. p. 58–63.
- [9] Lorestani AZ, Bidgoli AM, Dezfoli MA. Improve breast cancer detection in mammography images using neuro-fuzzy (ANFIS). *International Journal of Advanced Research in Computer Science*. 2013; 4(10):157–60.
- [10] Sivakumar R, Karnan M, Deepa GG. An improved modified tracking algorithm hybrid with fuzzy c means clustering in digital mammograms. *International Journal of Computer Technology and Applications*. 2012; 3(2):729–3
- [11] Xu S, Liu H, Song E. Marker-controlled watershed for lesion segmentation in mammograms. *Journal of digital imaging*. 2011; 24(5):754–63.
- [12] Dheeba J, Tamil Selvi. Bio inspired swarm algorithm for tumour detection in digital mammogram. In: Panigrahi BK, Das S, Suganthan PN, Dash SS, editors. *SEMCCO 2010. First International Conference on Swarm, Evolutionary and Memetic Computing*; 2010 Dec 16–18; Chennai, India: Berlin Heidelberg: Springer. p. 404–15.
- [13] Kuo Y-C, Lin W-C, Hsu S-C, Cheng A-C. Mass detection in digital mammograms system based on PSO algorithm. *IEEE International Symposium on Computer, Consumer and Control (IS3C)*; 2014 June 10–12; Taichung, Taiwan. p. 662–8. doi:10.1109/IS3C.2014.178.
- [14] Mini MG, Devassia VP, Thomas T. Multiplexed Wavelet transform technique for detection of microcalcification in digitized mammograms. *Journal of Digital Imaging*. 2004; 17(4):285–91.
- [15] Tiedeu A, Daul C, Kentsop A, Graebing P, Wolf D. Texture-based analysis of clustered microcalcifications detected on mammograms. *Digital Signal Processing*. 2012; 22(1):124–32.
- [16] Wang TC, Karayiannis NB. Detection of microcalcifications in digital mammograms using wavelets. *IEEE Transactions on Medical Imaging*. 1998; 17(4):498–509.
- [17] Dheeba JN, Singh A, Tamil Selvi S. Computer-aided detection of breast cancer on mammograms: A swarm intelligence optimized wavelet neural network approach. *Journal of Biomedical Informatics*. 2014; 49:45–52.
- [18] Jen C-C, Yu S-S. Automatic detection of abnormal mammograms in mammographic images. *Expert Systems with Applications*. 2015; 42(6):3048–55.
- [19] Zhang X, Homma N, Goto S, Kawasumi Y, Ishibashi T, Abe M, Sugita N, Yoshizawa M. A hybrid image filtering method for computer-aided detection of microcalcification clusters in mammograms. *Journal of Medical Engineering*. 2013; 1–8.
- [20] Rahmati P, Adler A, Hamarneh G. Mammography segmentation with maximum likelihood active contours. *Medical Image Analysis*. 2012; 16(6):1167–86.
- [21] Rouhi R, Jafari M, Kasaei S, Keshavarzian P. Benign and malignant breast tumors classification based on region growing and CNN segmentation. *Expert Systems with Applications*. 2015; 42(3):990–1002.
- [22] Beura S, Majhi B, Dash R. Mammogram classification using two dimensional discrete wavelet transform and gray-level co-occurrence matrix for detection of breast cancer. *Neurocomputing*. 2015; 154:1–14.
- [23] Srivastava S, Sharma N, Singh SK, Srivastava R. A combined approach for the enhancement and segmentation of mammograms using modified fuzzy C-means method in wavelet domain. *Journal of Medical Physics*. 2014; 39(3):169–83.
- [24] Jenefer MB, Cyrilraj V. An efficient image processing methods for mammogram breast cancer detection. *Journal of Theoretical and Applied Information Technology*. 2014; 69(1):32–9.
- [25] Oliver A, Freixenet J, Marti J, Perez E, Pont J, Denton ERE, Zwiggelaar R. A review of automatic mass detection and segmentation in mammographic images. *Medical Image Analysis*. 2010; 14(2):87–110.
- [26] Ramani R, Suthanthiravanitha S, Valarmathy S. A survey of current image segmentation techniques for detection of breast cancer. *International Journal of Engineering Research and Applications (IJERA)*. 2012; 2(5):1124–9.
- [27] Shanmugavadivu P, Sivakumar V, Suhanya J. Wavelet transformation-based detection of masses in digital mammograms. *International Journal of Research in Engineering and Technology*. 2014; 3(2):131–8.

- [28]Durai SMA, Kannan A, Narayana SN. Fuzzy classification model assisted by intensity based approach and segmenta tion for breast cancer detection and diagnosis. International Journal of Advanced Research in Computer Science. 2010; 1(3):398–402.
- [29]Dubey RB, Hanmandlu M. Gupta SK. Level set detected masses in digital mammograms. Indian Journal of Science and Technology. 2010; 3(1):9–13.
- [30]Rao VNT, Govardhan A. Efficient segmentation and classification of mammogram images with fuzzy filtering. Indian Journal of Science and Technology. 2015; 8(15):18.
- [31]M.P.Sukassini,T.Velmurugan. A survey on the analysis of Segmentation technique in mammogram image. Indian Journal of Science and Technology. 2015;8(22):